

BODY STRUCTURE AND ITS IMPORTANCE TO DENTAL WORK

SUBJECTS COVERED:

- Background
- Interceptive Orthopedic Orthodontics
- References

The author of the article below is [LaVar Riniker, DDS](#), retired. It was written in October 2000 for the "Holistic Dental Journal" and is reprinted here with permission.

Structural Implications of Interceptive Orthopedic Orthodontics


Background

The process of orthodontic correction in most orthodontic offices is palliative. Palliative? What do we mean palliative? If a drug does not get to the cause of a problem, we all understand that this drug alleviates symptoms and does not correct or cure the disease in question (ie. pain pills). Similarly orthodontics does not usually correct the underlying problem.


We can make the teeth look straighter, but if we do not correct the underlying problem; we are merely giving this teenager or adult a palliative fix that looks better for a time. The underlying problem will still be there and the end result is chaos of the first order. I emphasize the word "chaos" because this is the misunderstood portion of the structural equation. Chaos implies out of control implications of a large magnitude. The implications are for continued and cascading problems with little hope for improvement. I believe that the improper correction of



[Latex Allergy
Resource Guide](#)



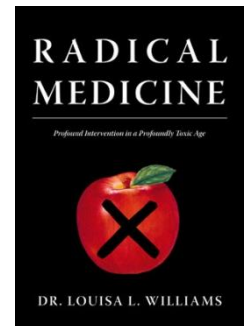
[Latex-Free Dentistry](#)




[Complete Guide to
Latex Allergy](#)




[Latex-Free
First Aid Kit](#)




[Radical Medicine](#)



[The 6-Channel AM/FM
Technique](#)



[Basic and
Advanced AM/FM
Manual](#)

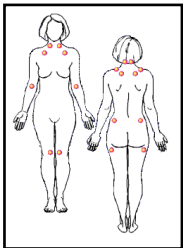


[EcoBiotics](#)


PACIFIC NORTHWEST FOUNDATION



[Chelita: A Cancer Survivor' Story](#)



[Overcoming Fibromyalgia](#)



[Pleomorphic Compendium](#)




[T-shirt](#)

teeth can lead to root canals, early loss of teeth, and usually extreme amounts of pain, expense and improperly completed dental work. (I spent nearly twenty-five years working on those chronic untreated problems, generally treating people for Cranio-Cervico-Mandibular Dysfunction) pain in the mouth and jaws due to this improperly treated structural problem.


We must begin understanding orthodontic problems for what they really mean in order to properly understand where I am coming from. The treatment of orthodontics is usually for the cosmetic improvement so that a beautiful smile is assuring a confident and successful adult person. We are all aware that a person without an inviting smile will not be trusted or promoted into the leadership positions that our society heralds and rewards. We do not elect our leaders unless they possess nearly every component of intelligence, poise, and success. (We have all experienced adults that have risen far beyond their parents, vision)

The crooked smile will not conjure this image, but how does this tie into the chaos we spoke of in dental work? The underlying causes of crooked and crowded teeth are three-dimensional structural imbalances of the whole body. Let me emphasize, Three-Dimensional Structural Imbalances and I do mean the whole body. The main cause of these narrow jaws and overlapping teeth is birth trauma. The [Osteopathic](#) profession has taught us that the compressions of the head in birth trauma are not properly improved merely by waiting to see if the head looks symmetrical.


The Osteopaths will tell us that the cosmetic improvement often leaves us with jammed cranial bones and twisted pelvises. Jammed cranial bones are the major cause of "Headaches". How can this be; if that were true, why wouldn't we just un-jam these bones to treat headaches? The key to this question, lies in the second phrase twisted pelvises. If your pelvis is twisted, the ultimate cause is related to the jammed cranial bones; the age old chicken and egg question? Why can't we un-jam the cranial bones and allow the pelvis to




[Clinical EcoBiotics](#)



[Neural Kinesiology \(aka A.R.T.\)](#)



[Muscles of the Lower Back & Abdomen](#)

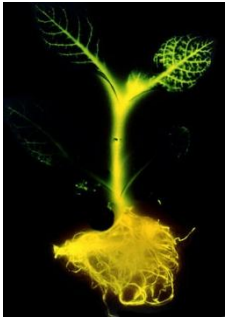

[Muscles of the Lower Extremities](#)


PACIFIC NORTHWEST FOUNDATION




[Coffee: To Drink, or Not to Drink?](#)



[Genetically Engineered Food](#)



[Q2 B.E.F.E.](#)




[Multiwave Oscillator](#)

unwind itself?


Well we might be able to, if the jamming is not too severe. We might also succeed if we do it early enough. (There are many successful treatments done to infants by Cranial Osteopaths) The major societal problem is that we do not do this un-jamming at all. Even when we correct the problem it is due to chronic symptoms, (hip pain, neck pain, ear problems, and headaches, in adults) usually; the body has "adapted" erroneously and our corrections are generally unsuccessful. The ideal treatment time is right after the birth trauma. The ideal practitioner is the Cranial Osteopath and the earlier the treatment; the more likely there will be a successful correction and not another "palliative" treatment. Societally we spend millions of dollars on repeated visits to the chiropractor for relief, or the pharmacist for pain pills, or other medications.

The best time to treat twisted pelvises is also in infancy. We have a tremendous opportunity to successfully treat and correct permanently these problems. The classic early symptom of all these maladies is a narrow face and a long face. How then does all this tie into our orthodontic crowding? The long narrow face is going to have crowded and overlapping teeth, but children will not normally be orthodontically treated until all the permanent teeth are erupted. Therefore the orthodontic treatment becomes palliative. (Many times the orthodontist has teeth removed so that he has less widening to accomplish generally this is not warranted)


Can there be corrective orthodontic treatment after the permanent teeth all come in? (This will be covered at another time) The answer is yes, but by then it is an enormously difficult process. The better time to treat your child would be between the ages of five and nine; treat them before the growth and complications of crowding have fully manifest themselves. You must also address the structural full body components in order to achieve the more permanent corrections that we desire. There are other complications of allergies, stress, and nutritional factors that may need to be addressed to complete the optimal corrective measures. (These



[Clinical Kinesiology: Muscles of the Upper Extremities](#)



[Clinical Kinesiology Travel Manual](#)



[Clinical Kinesiology Instruction Manual](#)



[Clinical Kinesiology TMJ & Hyoid Muscles](#)

PACIFIC NORTHWEST FOUNDATION

complications do not affect most children, but will be addressed later)

Interceptive Orthopedic Orthodontics

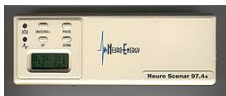Structurally speaking then the child will have narrow face and jaws, overlapping teeth, and jammed cranial bones, with a twisted pelvis. The classic way we are licensed as practitioners in most countries is to individually license us and to allow no overlapping of therapies even if we have dual licenses. (This problem has major political implications beyond the scope of this article). The best solution today is to combine therapies with both practitioners understanding and on board with these values in treatment. (I have successfully been a part of these efforts with many practitioners and they can work well when values and treatment goals are similar).

I am sure that there are also children with milder cases of this malady that will still benefit even without extreme complications of any of these symptoms. The more twisted illustrations are helpful for better understanding. I will include children with habitual bruxing or grinding of their teeth. Those that have early missing back teeth and symptoms of headaches, and neck pain would also merit treatment. The best way to evaluate twisted pelvises is to check the leg length, like your practitioner of any bodywork therapy will often do.


The key to this treatment is to have the bodywork done prior to changes in the dental components. The first step in changes for the dental components is merely to place the jaws in neutral while the bodywork is in process. These changes are best completed on children with teeth separation that allows the proprioceptive influence of the nervous system to be neutralized. (Proprioception is the automatic feedback to the brain that influences how we chew and even talk) The neutralization of the proprioception necessarily should be semi-permanent to prevent the child under treatment from negating the therapy. The way that this can be done in a safe and reversible method is by layering tooth colored filling



[Biomodulator](#)



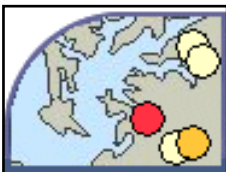[SCENAR](#)




[Toxicity Study](#)




[Our Toxic Times](#)




[TOXMAP](#)




[NCCAM](#)



[Homotoxicology
Materia Medica I](#)



[Homotoxicology
Materia Medica II](#)




[Isopathic/
Homeopathic
Materia Medica](#)

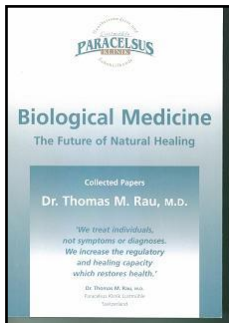
PACIFIC NORTHWEST FOUNDATION



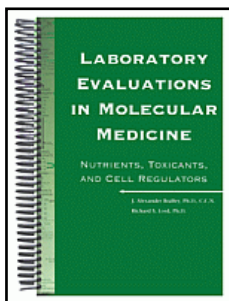
[My AminoPlex](#)



[Advanced Applied Microscopy](#)



[Biological Medicine](#)




[Laboratory Evaluations in Molecular Medicine](#)

materials over the posterior teeth.

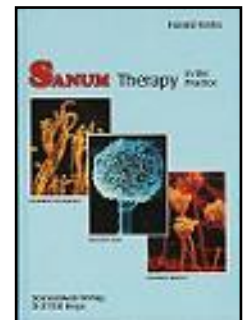
This when initially done is the method of neutralizing the proprioception. You can then have more ideal structural correction, and when this is optimal proceed to a more definitive layering of this material on the teeth. (We must have you see the bodywork therapist immediately before the dentist, with no eating in between appointments) There is often a thicker layer of material on the more posterior teeth than the anterior teeth. In many cases the anterior teeth may be touching, with significant space due to the layering between the back teeth. How is this possible you may ask. Well, the spacing material is shimming up the teeth and taking tightness and pressure off the muscles that open and close the jaws. This in turn will allow the jammed cranial bones and twisted pelvis to be in balance and harmony with the jaws. (This can be done to correct Class II bites [under bites] also; the dentist must use "twin block concepts".)

If you are correctly following our three-dimensional process, you may still be wondering how the jaws get wider and teeth less crowded? I can assure you if we are not too far into the developmental process of the body (between the ages of five and nine). The muscles that are part of the swallow and chewing of the mouth are capable of working on both sides of the teeth to make the widening occur naturally. We often add a simple swallow therapy to the child in question to aid in the proper use of the tongue during swallowing. This is accomplished by placing the tongue in the roof of the mouth and swallowing gently such that no lip movement is necessary during swallowing. We want to actually eliminate all lip and tongue thrusting activity but practice, is important.

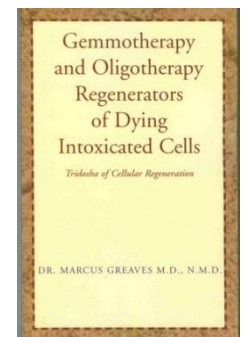
The dentist before treatment must understand the preceding explanations; and bodywork will need to be understood and supported by the dentist. The body treatments in question are very typical of what Cranial Osteopaths, Cranial Chiropractors, Cranially trained Physical Therapists, and Cranial Massage Therapists (in states where they can insert there hands into the mouth) will understand. There are dentists trained to do



[Coping with Food Intolerances](#)



[Sanum Therapy](#)



[Gemmotherapy and Oligotherapy Regenerators of Dying Intoxicated Cells](#)

PACIFIC NORTHWEST FOUNDATION

extensive cranial work but they are not usually allowed to work on all parts of the structural body by licensure.

We are, by the explanations venturing into arenas that are considered holistic, integrative and alternative to traditional training and understanding. This will change in time, but you may need the benefit for your five to nine year old sooner than this change will occur by historical standards.

For more information on this and related topics, see the references below.

The information contained herein has been obtained from a variety of sources. This document is presented to increase awareness of the topic and educate the general public. It is not intended to be an extensive discussion of this subject, or to provide specific treatment guidelines.

REFERENCES


Dental Kinesiology Reference Sheet: shows relations between individual teeth, muscles, organs, nutritional alternatives, and meridians

Names of teeth: the Palmer Notation, which is the most commonly used system to name teeth


Optimal Health Dentistry: Dr. LaVar Riniker's web site

Teeth to Body Chart: relation between specific teeth and joints, vertebrae, organs, endocrine glands, tissue systems, sense organs, and others.

Tooth/Muscle Chart: relation between specific teeth and various muscles throughout the human body.



[Trace Elements and Other Essential Nutrients](#)



[PharmFacts for Nurses](#)